Dementia and Neurocognitive Disorders 2013; 12: 29-32
http://dx.doi.org/10.12779/dnd.2013.12.29.1

■ CASE REPORT ■

Serial Changes in Diffusion-Weighted Magnetic Resonance Images with Hypoperfusion on Brain SPECT in a Case of Hashimoto's Encephalopathy: Understanding Pathophysiology of Hashimoto's Encephalopathy

Sung Jae Kim, M.D.*, Eun Hwan Jeung, M.D.*, Mi Kyung Park, M.D.†, Sunseob Choi, M.D.‡, Kyung Won Park, M.D.*

Departments of Neurology*, Endocrinology†, Radiology‡, Dong-A University College of Medicine, Busan, Korea

Received: August 13, 2012
Revision received: February 12, 2013
Accepted: February 12, 2013

Address for correspondence
Kyung Won Park, M.D.
Department of Neurology, Dong-A University College of Medicine, 32 Daesingongwon-ro, Seo-gu, Busan 602-714, Korea
Tel: +82-51-240-2966
Fax: +82-51-245-2966
E-mail: neuropark@dau.ac.kr

*This study was supported by a grant from the Korea Healthcare Technology R&D Project, Ministry for Health, Welfare & Family Affairs, Republic of Korea (A102065).

Diffuse or focal white matter hyperintensity lesions on MRI have been reported in only a few patients with Hashimoto's encephalopathy (HE), and anti-TPO antibody level is high in most cases. We report a 59-year-old woman who presented with acute onset of disorientation with confusion. Anti-thyroglobulin antibody was detected in high titer, although anti-TPO antibody titer was not high. Thyroid sonography and biopsy revealed Hashimoto's thyroiditis. Initial fluid-attenuated inversion recovery (FLAIR) image and diffusion-weighted imaging (DWI) revealed ill-defined, diffuse, high-signal intensity lesions on the deep white matters and globus pallidus. Brain SPECT showed significant hypoperfusion in both basal ganglia (especially globus pallidus), frontal and temporal lobes. With the impression of HE, the patient was treated on a high-dose steroid. Over the next 15 weeks, her cognition improved to a nearly normal state and the MRI findings on DWI and FLAIR showed resolution paralleling her clinical improvement. Our case illustrates the peculiar changes in the MR findings, especially in DWI, with hypoperfusion on brain SPECT in patients with HE and allows for a greater understanding of the pathophysiology of HE.

Key Words: *Hashimoto's encephalopathy, Magnetic resonance imaging, Diffusion-weighted imaging, SPECT*

INTRODUCTION

Hashimoto's encephalopathy (HE) is a disease accompanied by various neuropsychological manifestations, including cognition or consciousness deterioration, personality changes, and seizures or hallucinations [1]. Recently, HE has attracted increased attention because it is regarded as a cause of treatable dementia and has also been recognized as one of the important differential diagnoses of Creutzfeldt-Jakob disease. HE often shows increased anti-thyroglobulin (anti-Tg) antibody and anti-thyroperoxidase (anti-TPO) antibody levels and may respond positively to steroid treatment [1]. Although autoimmune reactivities are thought to be an underlying pathomechanism in HE, the etiology of the disease is still incompletely understood. When HE occurs, thyroid hormones are at a normal level or may indicate only a mild decrease in thyroid function. Therefore, an anti-thyroid antibody test should be carried out in addition to a thyroid function test [2].

Brain magnetic resonance imaging (MRI) in HE patients reveals heterogeneous findings, from entirely normal findings to various degrees of nonspecific abnormalities such as focal or diffuse hyperintensities on either side of the brain pa-

© 2013 Korean Dementia Association
This is an Open Access article distributed under the terms of the Creative Commons Attribution Non-Commercial License (http://creativecommons.org/licenses/by-nc/3.0) which permits unrestricted non-commercial use, distribution, and reproduction in any medium, provided the original work is properly cited.

renchyma. Few cases have reported serial, diffusion-weighted imaging (DWI) follow-up evaluations in patients with HE [3, 4]. We report a distinct case of HE showing global hypoperfusion on brain SPECT and marked improvement on DWI and FLAIR images after high-dose steroid therapy, and we will discuss pathophysiology of Hashomoto's encephalopathy by interpretation of imaging findings of brain SPECT and serial changes of brain MRI in this case.

CASE REPORT

A 59-year-old female patient presented with feelings of disorientation and confusion over a period of three weeks. She indicated that she was experiencing disorientation of time, vacant feelings, was not speaking much, had reduced memory function, and had a slower gait. There were no other significant diseases indicated in her medical or family history. The patient's physical examination showed a thyroid that was within normal limits of size and hardness; she did not exhibit any signs of illness.

At initial presentation, the patient showed clear consciousness in neurological examination. While her orientation toward place and people was normal, her time orientation was significantly decreased. The Korean version of the mini-mental state examination (K-MMSE) showed a score of 15/30, reflecting a significant impairment. Detailed neuropsychological tests showed multiple cognitive deficits, including memory, orientation to time and place, and frontal executive function. She walked very slowly and showed slight bradykinesia. However, she did not exhibit tremors, spasticity, or other symptoms associated with her extrapyramidal system. In addition, neurological abnormalities such as muscle weakness, abnormal sensation, or ataxia were not observed. Her blood tests demonstrated normal values, as did her thyroid function test. Analysis of her cerebrospinal fluid (CSF) revealed normal levels of sugars and proteins and the absence of inflammatory cells. However, her anti-Tg antibody level showed a significant increase to 334.95 IU/mL (normal ≤ 70 IU/mL) and her anti-TPO antibody level was 34.86 IU/mL (normal ≤ 60 IU/mL), and other antibodies were negative about neutrophil cytoplasmic (ANCA), nuclear (ANA), SSA, SSB, dsDNA, Jo-1 and Scl-70. Ultrasound of her thyroid showed a diffuse, irregular, hypoechoic change. A cone-biopsy of her thyroid gland showed a lymphoid follicle and Hürthle cell changes around the follicular epithelium (Fig. 1), confirming HE.

Brain MRI, using DWI, T2-weighted images, and FLAIR, showed a wide array of high-signal intensities, mainly on the deep white matter. The FLAIR and T1-weighted image showed focal, rounded, high-signal intensity lesions on both parts of the globus pallidus (Fig. 2). Single-photon emission computed tomography (SPECT) of the brain showed significant hypoperfusion in both basal ganglia (especially globus pallidus), frontal and temporal lobes at admission (Fig. 3). With a diagnosis of HE, the patient was treated with a high dose of steroid (methylprednisolone 1 g/day) for 7 days. Subsequently, she took steroid pills for an additional 4 weeks, while gradually decreasing the dosage. After 4-5 days of steroid treatment, her bradykinesia improved and she spoke more. After 4 months, her disorientation, cognition level, and physical function improved to a level almost similar to her previous level. A follow-up brain MRI, taken 15 weeks after initial presentation, showed marked improvement on DWI and FLAIR images, but the lesions in both parts of the globus pallidus lost their high-signal intensities, and changed into cyst like lesions (Fig. 2). In addition, the follow-up blood test confirmed normal levels of anti-Tg antibody (60.65 IU/mL) and anti-TPO antibody (18.97 IU/mL).

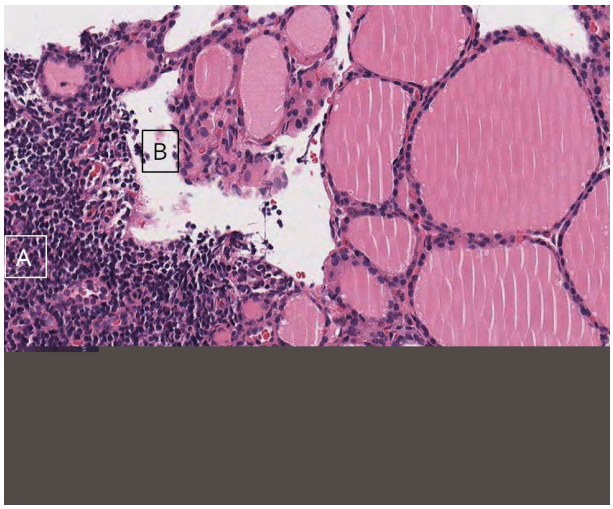

Fig. 1. Cone biopsy of thyroid. Infiltration of lymphoid foillicle (A) and Hürthle cell change of surrounding follicular epithelial cells (B).

Tg antibodies combine with thyroglobulin (required for producing thyroid hormone), which is also often increased in HE patients [1, 2]. Other antibodies, such as the anti-α-enolase antibody, are known to be somewhat more unique to HE. Anti-α-enolase antibodies are distributed inside vascular endothelial cells, explaining why they are considered supportive evidence for vasculitic symptoms of HE [1]. In our case, only the anti-Tg antibody increased to abnormal levels, but recovered after steroid treatment. This observation supports the idea that normalization of the anti-Tg antibody titer can be related to improvement in the patients' condition [6]. Moreover, there was a comment that anti-TPO antibodies were positive in almost HE cases [1], but there was no large study about incidences of anti-TPO & anti-Tg antibody in HE cases. Recent studies reported 27 patients with HE that 23 patients (85%) showed high titer of both antibodies, 2 patients (7.5%) showed high titer of anti-TPO antibody, and 2 patients (7.5%) showed only high titer of anti-Tg antibody [2, 6, 7]. MRI, SPECT, and positron emission tomography are commonly used to evaluate brain disorders in HE patients. MRI shows variable findings, with 50% of patients appearing to be normal, while others show nonspecific findings, such as ischemic changes, demyelination, vasogenic edema, or atrophy [1, 4]. Among these findings, bilateral and focal or diffuse high-signal intensity changes in the subcortical area are the most common [1, 5, 8]. In addition, MRIs show different findings over time, and can show improvement after steroid treatment [3, 4, 8]. Our patient showed widespread diffuse hyperintense lesions on the deep white matter in DWI, T2-weighted, and FLAIR images, and those disappeared in concert with clinical improvement after corticosteroid treatment, but the lesions in both globus pallidus lost their high-signal intensities, and changed into cyst like lesions. Brain SPECT showed significant hypoperfusion in both basal ganglia, frontal and temporal lobes at admission. Forchetti et al. [9] reported global hypoperfusion on brain SPECT in HE patients, and it could be a pathophysiology of HE by autoimmune cerebral vasculitis.

We suggest that the marked improvement of the diffuse hyperintense lesions in DWIs reflect mixed cytotoxic/vasogenic edema resulting from a temporary ischemic injury in the brain tissue associated with brain hypoperfusion. Moreover, the reason for the remnant lesions of high-signal intensity and subsequent change to a cystic form may be the permanent neuronal damage associated with significant hypoperfusion on brain SPECT in both areas of globus pallidus caused by autoimmune reactivity [9].

The current case emphasizes the importance of including DWI in the imaging evaluation of patients with HE in order to assess the possible mechanism of vasculitic changes and to provide another measure of response to steroid therapy. Our case illustrates the peculiar changes in the MR findings, especially in DWI, with hypoperfusion on brain SPECT in patients with HE and allows for a greater understanding of the pathophysiology of HE.

REFERENCES

1. Nicoline Schiess, Carlos A. *Pardoa. Hashimoto's Encephalopathy. Ann NY Acad Sci 2008; 1142: 254-65.*
2. Ferracci F, Moretto G, Candeago RM, Cimini N, Conte F, Gentile M, *et al. Anti-thyroid antibodies in the CSF: their role in the pathogenesis of Hashimoto's encephalopathy. Neurology 2003; 60: 712-4.*
3. Grommes C, Griffin C, Downes KA, Lerner AJ. *Steroid-responsive encephalopathy associated with autoimmune thyroiditis presenting with diffusion MR imaging changes. AJNR Am J Neuroradiol 2008; 29: 1550-1.*
4. Chen C, Qin W, Wei C, Wang X, Li K. *Time course of Hashimoto's encephalopathy revealed by MRI: Report of two cases. J Neurol Sci 2011; 300: 169-72.*
5. Mijajlovic M, Mirkovic M, Dackovic J, Zidverc-Trajkovic J, Sternic N. *Clinical manifestations, diagnostic criteria and therapy of Hashimoto's encephalopathy: report of two cases. J Neurol Sci 2010; 288: 194-6.*
6. Blanchin S, Coffin C, Viader F, Ruf J, Carayon P, Potier F, *et al. Anti-thyroperoxidase antibodies from patients with Hashimoto's encephalopathy bind to cerebellar astrocytes. J Neuroimmunol 2007; 192: 13-20.*
7. Kothbauer-Margreiter I, Sturzenegger M, Komor J, Baumgartner R, Hess CW. *Encephalopathy associated with Hashimoto thyroiditis: diagnosis and treatment. J Neurol 1996; 243: 585-93.*
8. Chang T, Riffsy MT, Gunaratne PS. *Hashimoto encephalopathy: clinical and MRI improvement following high-dose corticosteroid therapy. Neurologist 2010; 16: 394-6.*
9. Forchetti CM, Katsamakis G, Garron DC. *Autoimmune thyroiditis and a rapidly progressive dementia: global hypoperfusion on SPECT scanning suggests a possible mechanism. Neurology 1997; 49: 623-6.*